

A Cadaveric Study of Two Uncommon Cases of Sural Nerve Complex Variation

Ovidiu-Ioan Şuşu, Rareş Vodă, Klara Brînzaniuc, Tamás Csaba Sipos, Zsuzsanna Pap

Department of Anatomy and Embryology, "George Emil Palade" University of Medicine, Pharmacy, Science and Technology, Târgu Mureş, Romania

CORRESPONDENCE

Tamás Csaba Sipos

Str. Gheorghe Marinescu nr. 38
540139 Târgu Mureş, Romania
Tel: +40 265 215 551
Email: tamas.sipos@umfst.ro

ARTICLE HISTORY

Received: June 29, 2023
Accepted: August 1, 2023

Ovidiu-Ioan Şuşu • Str. Gheorghe Marinescu nr. 38,
540139 Târgu Mureş, Romania. Tel: +40 265 215 551,
Email:

Rareş Vodă • Str. Gheorghe Marinescu nr. 38, 540139
Târgu Mureş, Romania. Tel: +40 265 215 551, Email:

Klara Brînzaniuc • Str. Gheorghe Marinescu nr. 38,
540139 Târgu Mureş, Romania. Tel: +40 265 215 551,
Email:

Zsuzsanna Pap • Str. Gheorghe Marinescu nr. 38,
540139 Târgu Mureş, Romania. Tel: +40 265 215 551,
Email:

ABSTRACT

Introduction: The sural nerve is a sensitive nerve whose function is to provide sensory supply for the posterolateral aspect of the distal third of the leg and the lateral side of the dorsum of the foot. This nerve is formed in the upper third of the calf from the terminal branches of the tibial and common peroneal nerves and the communicating branch of the sural nerve. **Objectives:** The aim of our study is to showcase two anatomical variants of the sural nerve. **Materials and methods:** Two formalin-preserved cadavers, one male and one female, embalmed using formalin 4% were dissected with the intent of being used as teaching materials for the students attending anatomy classes at the "George Emil Palade" University of Medicine, Pharmacy, Science and Technology of Târgu Mureş, Romania. **Results:** In both cases, less common anatomical variations of the formation of sural nerve were discovered. On the male cadaver, we identified the sural nerve as a continuation of the medial sural cutaneous nerve. The lateral sural cutaneous nerve and the communicating branch of the sural nerve were both absent. On the female cadaver, we identified both the medial sural cutaneous nerve and the lateral sural cutaneous nerve. The sural nerve was, however, a continuation of only the lateral sural cutaneous nerve, with the medial sural cutaneous nerve as an independent branch. **Conclusions:** We described two anatomical variants of the sural nerve, which are less common than those documented in the literature.

Keywords: sural nerve complex, variation

INTRODUCTION

The sural nerve, also known as the saphenous nerve due to its course alongside the small saphenous vein in the posterior leg, is a sensitive subcutaneous nerve located in the central axis on the posterior aspect of the calf, between the calcaneal tendon and the lateral malleolus. Its main function is to provide sensory supply for the posterolateral aspect of the distal third of the leg and the lateral side of the dorsum of the foot.¹⁻⁴

In most cases, the sural nerve is formed in the upper third of the calf, from a lateral branch, a medial branch, and the communicating branch of the sural nerve. This anastomosis represents a direct communication between the tibial nerve and the common peroneal nerve.^{1,3,5-8} The medial branch is represented

TABLE 1. Variations of sural nerve formation in the literature

Variant	Origin of the sural nerve
A	MSCN (TN) + SCB (SCB arises from LSCN; LSCN arises from CPN)
B	MSCN (TN) + SCB (LSCN and SCB arise from the bifurcation of a CPN branch)
C	MSCN (TN) + SCB (SCB and LSCN arise independently from CPN)
D	MSCN (TN) + SCB (SCB arises from CPN; LSCN arises from SCB)
E	MSCN + SCB (SCB arises from CPN; absent LSCN)
F	MSCN (TN) (SN is a continuation of MSCN; absent LSCN and SCB)
G	MSCN (TN) (SN is a continuation of MSCN; independently present LSCN; absent SCB)
H	MSCN (TN) arises from SCB (distal third of the leg); SN is a continuation of LSCN (CPN)
I	MSCN (TN) independently present, up to the heel; SN is a continuation of LSCN (CPN); absent SCB
J	MSCN (two independent branches from TN: TCB1 + TCB2); SN is a continuation of MSCN; absent LSCN and SCB
K	MSCN (two independent branches from TN: TCB1 + TCB2); SCB arises from LSCN
L	MSCN (TN) + NFCP; independent LSCN; absent SCB
M	MSCN (SCN); SN is a continuation of MSCN; absent LSCN and SCB
N	SCB arises from MSCN (TN) (proximal third of the leg); SN = SCB + LSCN (CPN)
O	Independent MSCN (TN) present up to the proximal third of the leg; SN is a continuation of LSCN (CPN); absent SCB
P	SN is a continuation of LSCN (CPN); absent MSCN

SN, sural nerve; SCN, sciatic nerve; LSCN, lateral sural cutaneous nerve; MSCN, medial sural cutaneous nerve; SCB, sural communicating branch; LDCN, lateral dorsal cutaneous nerve; TN, tibial nerve; CPN, common peroneal nerve; PCFN, posterior femoral cutaneous nerve; TCB, tibial connection branch

by the medial sural cutaneous nerve (MSCN), which originates from the tibial nerve (L4–S3) and descends between the two heads of the gastrocnemius muscle towards the central axis of the calf. After perforating the crural fascia, it joins the communicating branch of the sural nerve.^{2,3,7,9} The lateral branch, known as the lateral sural cutaneous nerve (LSCN), is a branch of the common fibular (peroneal) nerve (L4–S2), which emerges in the lateral side of the popliteal fossa. The communicating branch of the sural nerve originates from the common peroneal nerve or the lateral branch root of the common peroneal nerve and anastomoses with the medial sural cutaneous branch in the upper third of the calf.^{1,3,7,9}

Numerous anatomical variants have been described in the literature regarding the origin and course of the sural nerve (Table 1, Figure 1). Variations most commonly arise based on the presence or absence of the communicating branch of the sural nerve, which may be missing, have different origins, or even be supernumerary. Variants have been described where the MSCN or the LSCN is missing or does not participate in the formation of the sural nerve. The sural nerve branching from the tibial nerve superior to the popliteal fossa or from the sciatic nerve are among the less common variations.^{1,4,8}

The sural nerve is used as a graft site for the reconstruction of other peripheral nerves and for the diagnosis of various neurologic diseases through biopsy. Therefore, a com-

prehensive understanding of the level of formation, course, length, and proximity of the sural nerve to the small saphenous vein, gastrocnemius muscle, and calcaneal tendon are essential for both surgical and clinical practice.^{2,5,8,10–13} The aim of our study is to showcase two anatomical variations in the formation of the sural nerve and to provide further data in regards to the incidence of certain variants.

MATERIALS AND METHODS

We used two formalin-preserved cadavers, one male and one female, embalmed using formalin 4%. Both were dissected with the intent of being used as teaching material for the students attending anatomy classes at “George Emil Palade” University of Medicine, Pharmacy, Science and Technology of Târgu Mureş, Romania. In both cadavers, dissection was performed only on the left lower limb, as the contralateral leg was missing due to previously being amputated superior to the popliteal fossa. Therefore, comparative dissection could not be performed.

Ethics

This study was approved by the ethics committee of the “George Emil Palade” University of Medicine, Pharmacy, Science and Technology of Târgu Mureş (no. 2366/06.06.2023).

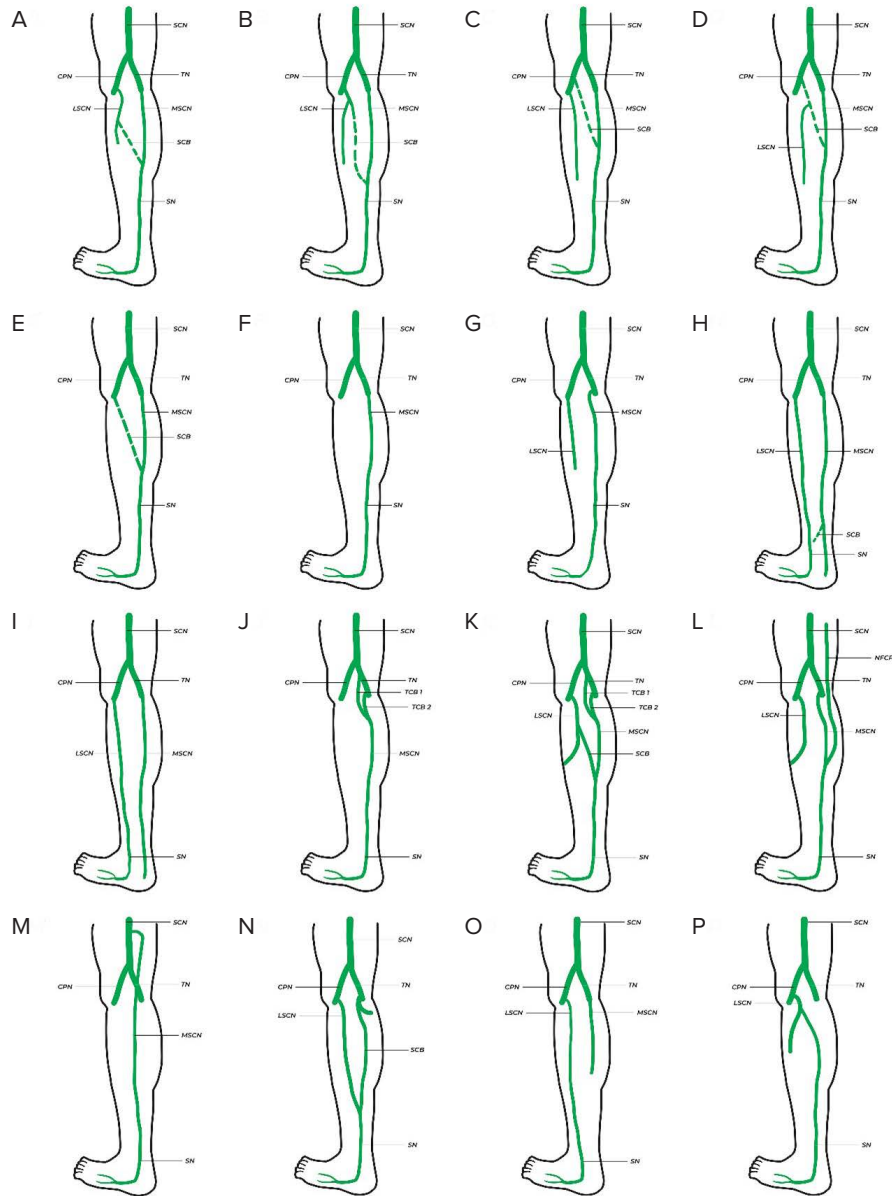


FIGURE 1. Formation and course variants of sural nerve as described in the literature

RESULTS

On the male cadaver, we identified the sural nerve as a continuation of the MCSN. The lateral sural cutaneous nerve and the communicating branch of the sural nerve were both absent. On the female cadaver, we identified both the MSCN and the LSCN. The sural nerve was however, in this instance, a continuation of only the LSCN, with the MSCN as an independent branch, and the communicating branch was completely missing.

DISCUSSION

The sural nerve is commonly used as a harvesting site for nerve grafts, being essential for in the reconstruction of

various peripheral nerves. Maxillofacial surgery makes use of these nerve grafts when reparation of the facial or inferior alveolar nerve is required after tumor extirpation or bone reconstruction. The removal of invasive retroperitoneal or pelvic tumors often also targets adjacent nerves, and the sural nerve can be used for ilioinguinal, femoral, or sciatic nerve reconstruction. It is also used in the diagnosis of pathologies associated with neurological damage such as diabetic neuropathy or acute inflammatory polyradiculoneuropathy (Guillen-Barré disease), both through electrophysiological studies and through its biopsy.^{2,5,8,10-13}

Multiple variants of the formation of the sural nerve have been documented in the literature. A study performed by Steele *et al.* on a group of 208 lower limbs described a total

TABLE 2. Statistical distribution of sural nerve formation variants, according to the literature

Study	Variant (%)								
	A	B	C	D	E	F	G	H	I
Ramakrishnan <i>et al.</i> ⁷			51.5		13.8		31.2		
Steele <i>et al.</i> ¹	12.02	13.46	7.69	8.17	8.65	8.65	25.96	10.58	3.85
Jeon <i>et al.</i> ²			41.34				34.61		
Riedl <i>et al.</i> ¹⁴			1.73		78.03		8.67		3.46
Büyükmumcu <i>et al.</i> ¹⁵	46.66	10	6.66			6.66	2.66		3.33
Our cases			35.83		34.16		20.83		4.16
						50			50

of 11 variants of formation of the sural nerve complex.¹ The most frequent patterns were type G, (n = 54; 25.96%), type B (n = 28; 13.46%), and type A (n = 25; 12.02%) (Table 2).

Studies conducted in our geographical area, such as those by Riedl *et al.* and Büyükmumcu *et al.*, show variant A as the most common, representing 46.66% and 35.83% of the total cases studied, respectively.^{14,15} In contrast, in the study of Jeon *et al.*, only 1.73% of the studied lower limbs presented this variant of sural nerve formation.²

In a meta-analysis performed by Ramakrishnan *et al.*, variants A, B, C, and D were grouped together and were present in 51.5% of the total cases described.⁷ In the study of Steele *et al.*, these variants were described separately, the sum of their incidences being 41.34%, with a relatively small difference compared to the previous study.^{1,8}

More notable differences were found in the case of type E. It was found to be rarer in the studies conducted by Steele *et al.* and Ramakrishnan *et al.*, with an incidence

of 8.65% and 13.8%, respectively.^{1,7} In contrast, Jeon *et al.* found this variant in 78.03% of cases.² In the study of Büyükmumcu *et al.*, type E was the second most frequent variant, with an incidence of 34.16% of the total dissected preparations.¹⁵

In this study, we described two anatomical variants of the sural nerve. In the lower left limb of a male corpse, we identified variant F, the sural nerve being present as a continuation of the MCSN, while the LSCN and the sural communicating branch were both absent. In the lower left limb of the female corpse, we identified variant I, in which the sural nerve was a continuation of the LSCN branch, and no apparent communication with the MSCN branch was present.

Similar to our case, Steele *et al.* found variant F of sural nerve formation (Figure 2) in 18 lower limbs (8.65%) in the studied group.¹ Studies conducted in our geographical area, show variant F to be present in 6.66% and 20.83% of

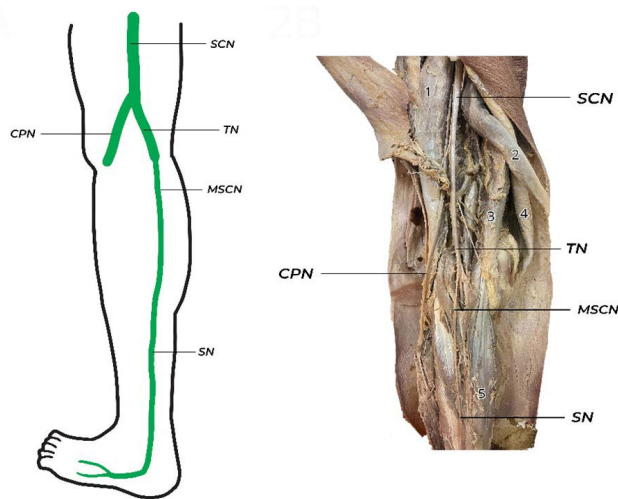


FIGURE 2. Variant F. 1 – Biceps femoris muscle; 2 – Semitendinosus muscle; 3 – Semimebranosus muscle; 4 – Gracillis muscle; 5 – Gastrocnemian muscle.

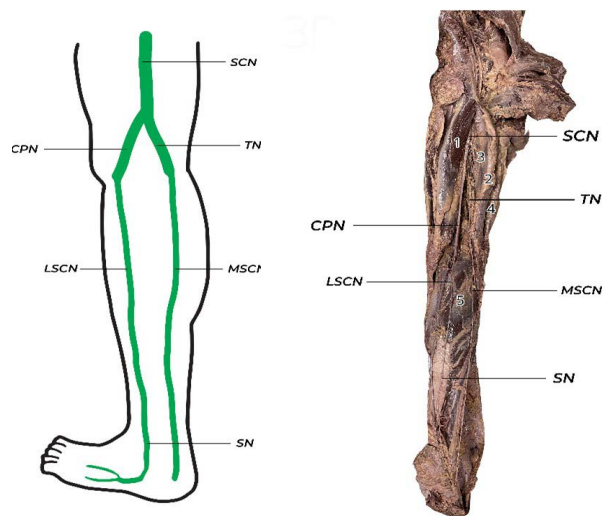


FIGURE 3. Variant I. 1 – Biceps femoris muscle; 2 – Semitendinosus muscle; 3 – Semimebranosus muscle; 4 – Gracillis muscle; 5 – Gastrocnemian muscle.

cases, respectively.^{14,15} In the group studied by Steele *et al.* in the USA, type F proved to be a rare variant, with an incidence of 8.65%.¹

Variants F and G described in the meta-analysis of Ramakrishnan *et al.* represented 31.2% of the studied group. Variant I (Figure 3), also described in this study, was found in approximately equal proportions by Steele *et al.*, Jeon *et al.*, and Riedl *et al.*, with an average incidence of 3.54%.^{1,2,7,8,14,15}

Among the extremely rare variants (n = 1; 0.48%) described by Steele *et al.* are variants O and P, currently not included in the classification system and not discussed separately in the study of Ramakrishnan *et al.*⁷ Similarly, very rare and still unrecognized variants were also identified by Büyükmumcu *et al.*, such as type J (n = 2; 2.5%), type K (n = 1; 0.83%), or L (n = 1; 0.83%).^{1,7,14,15}

CONCLUSIONS

Taking into consideration the role of the sural nerve in regards to peripheral nerve reconstruction using grafts, the importance of being aware of its variants cannot be denied. In this study, we described two of the less common variants, type F and type I.

CONFLICT OF INTEREST

The authors declare no conflict of interest.

REFERENCES

1. Steele R, Coker C, Freed B, Wright B, & Brauer, P. Anatomy of the sural nerve complex: Unaccounted anatomic variations and morphometric data. *Ann Anat.* 2021;238.
2. Jeon SK, Paik DJ, Hwang Y. Variations in sural nerve formation pattern and distribution on the dorsum of the foot. *Clinical Anatomy.* 2017;30:525–532.
3. Popieluszko P, Mizia E, Henry BM, et al. The surgical anatomy of the sural nerve: An ultrasound study. *Clin Anat.* 2018;31:450–455.
4. Seres-Sturm L, Branzaniuc K, Niculescu C, Şipoş R. *Anatomia Membrelor. Târgu Mureş, University Press, 2005*
5. Huelke DF. A study of the formation of the sural nerve in adult man. *Am J Phys Anthropol.* 1957;15:137–147.
6. Seema SR. Study of Sural Nerve Complex in Human Cadavers. *ISRN Anat.* 2013;2013:1–7.
7. Ramakrishnan PK, Henry BM, Vikse J, et al. Anatomical variations of the formation and course of the sural nerve: A systematic review and meta-analysis. *Ann Anat.* 2015;202:36–44.
8. Vuksanovic-Bozovic A, Radunovic M, Radojevic N, Abramovic M. The bilateral anatomical variation of the sural nerve and a review of relevant literature. *Anat Sci Int.* 2014;89:57–61.
9. Standring S. *Gray's anatomy: the anatomical basis of clinical practice.* 40th ed. London: Elsevier Churchill Livingstone, 2008
10. Tsuchihara T, Nemoto K, Arino H, Amako M, Murakami H, Yoshizumi Y. Sural nerve grafting for long defects of the femoral nerve after resection of a retroperitoneal tumour. *J Bone Joint Surg Br.* 2008;90:1097–1100.
11. Chang YM, Rodriguez ED, Chu YM, Tsai CY, Wei FC. Inferior alveolar nerve reconstruction with interpositional sural nerve graft: A sensible addition to one-stage mandibular reconstruction. *J Plast Reconstr Aesthet Surg.* 2012;65:757–762.
12. Lee MC, Kim DH, Jeon YR, et al. Functional outcomes of multiple sural nerve grafts for facial nerve defects after tumor- blative surgery. *Arch Plast Surg.* 2015;42:461–468.
13. Ruth A, Schulmeyer FJ, Roesch M, Woertgen C, Brawanski A. Diagnostic and therapeutic value due to suspected diagnosis, long-term complications, and indication for sural nerve biopsy. *Clin Neurol Neurosurg.* 2005;107:214–217.
14. Riedl O, Frey M. Anatomy of the sural nerve: Cadaver study and literature review. *Plast Reconstr Surg.* 2013;131:802–810.
15. Büyükmumcu M, Aydın Kabakçı AD, Akin Saygin D, Yılmaz MT, Şeker M. Sural nerve harvest for infants: Integrated with information based on anatomical dissections. *Turk J Med Sci.* 2021;51:473–482.