

# Atypical Atrial Tachycardia in a Newborn – a Case Report

Dorottya Gábor-Miklósi<sup>1</sup>, Andreea Cerghit-Paler<sup>1,2</sup>, Ioana Sus<sup>1,2</sup>, Simina Ghiragosian-Rusu<sup>1,2</sup>, Amalia Făgărășan<sup>1,2</sup>, Rodica Togănel<sup>1,2</sup>, Liliana Gozar<sup>1,2</sup>

<sup>1</sup> Emergency Institute of Cardiovascular Disease and Heart Transplant, Târgu Mureș, Romania

<sup>2</sup> “George Emil Palade” University of Medicine, Pharmacy, Science and Technology, Târgu Mureș, Romania

## CORRESPONDENCE

### Andreea Cerghit-Paler

Str. Gheorghe Marinescu nr. 38  
540139 Târgu Mureș, Romania  
Tel: +40 768 851 792  
E-mail: palerandreea@yahoo.com

## ARTICLE HISTORY

Received: June 25, 2022  
Accepted: August 27, 2022

**Dorottya Gábor-Miklósi** • Str. Gheorghe Marinescu nr. 50, Târgu Mureș, Romania. Tel: +40 265 216 368, E-mail: annadorka@yahoo.com

**Ioana Sus** • Str. Gheorghe Marinescu nr. 50, Târgu Mureș, Romania. Tel: +40 265 216 368, E-mail: sus.ioana@gmail.com

**Simina Ghiragosian-Rusu** • Str. Gheorghe Marinescu nr. 50, Târgu Mureș, Romania. Tel: +40 265 216 368, E-mail: simina\_r88@yahoo.com

**Amalia Făgărășan** • Str. Gheorghe Marinescu nr. 50, Târgu Mureș, Romania. Tel: +40 265 216 368, E-mail: amalia.fagarasan@umfst.ro

**Rodica Togănel** • Str. Gheorghe Marinescu nr. 50, Târgu Mureș, Romania. Tel: +40 265 216 368, E-mail: rodica.toganel@umfst.ro

**Liliana Gozar** • Str. Gheorghe Marinescu nr. 50, Târgu Mureș, Romania. Tel: +40 265 216 368, E-mail: liliana.gozar@umfst.ro

## ABSTRACT

We present the case of a neonatal patient with atrial tachycardia with unusual characteristics – abrupt onset and cessation, non-responsiveness to overdrive, termination by direct cardioversion – in association with an ostium secundum-type atrial septal defect and a large interatrial septum aneurysm. Electrocardiographic recordings showed P waves with characteristics suggesting a right low septal origin, which suggested a possible involvement of the septal aneurysm. In dealing with arrhythmias, a thorough echocardiographic evaluation is mandatory to identify underlying structural malformations and to evaluate the hemodynamic status. Further research should be made concerning mechanisms of arrhythmias in patients with an associated atrial septum aneurysm.

**Keywords:** interatrial septal aneurysm, atrial tachycardia, supraventricular arrhythmia, newborn, fetus

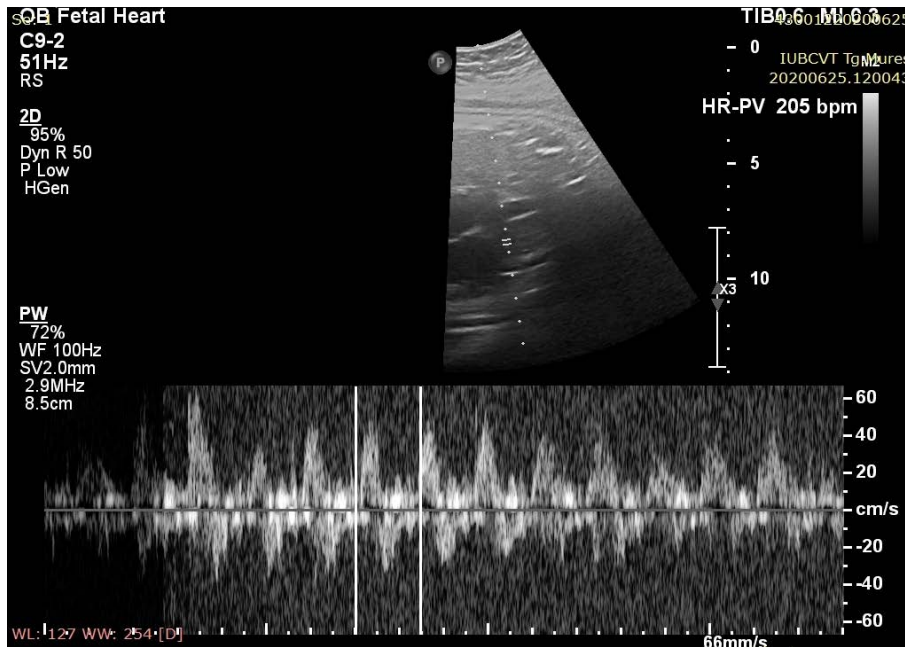
## INTRODUCTION

Fetal and early postnatal cardiac rhythm abnormalities can occur in up to 1–3% of cases, and assessment of these arrhythmias can be challenging.<sup>1</sup> In this age group, supraventricular tachycardia (SVT) occurs most commonly due to accessory pathway-mediated reentry circuits, but enhanced automaticity may also be the cause.<sup>1</sup>

## CASE PRESENTATION

A female patient in a stable clinical state, with an ongoing pregnancy of 36/37 gestational weeks was directed to our center due to fetal tachycardia observed by the caring gynecologist. Due to limitations imposed by the SARS-CoV-2 pandemic, the pregnancy lacked thorough follow-up, thus no exact information could be obtained regarding the onset of the dysrhythmia.

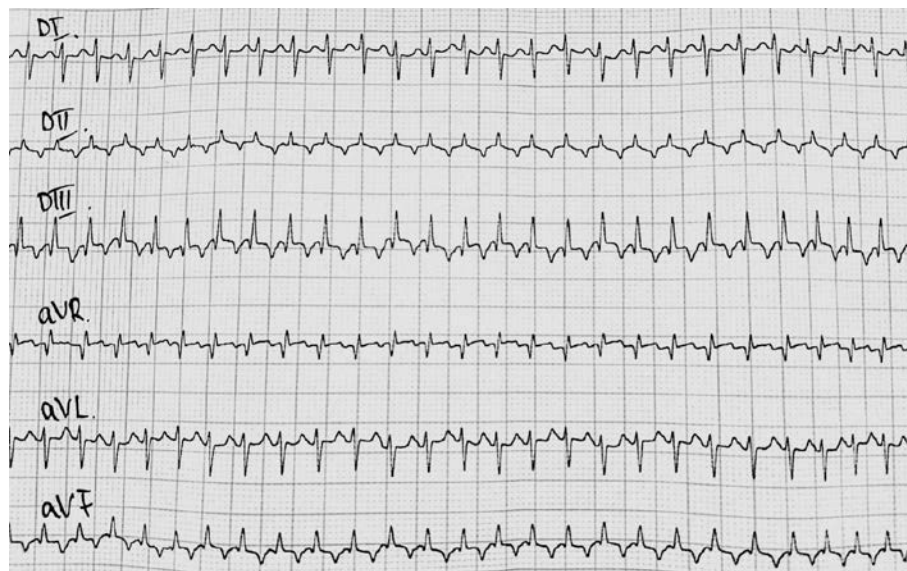Fetal echocardiographic assessment showed a regular tachycardia, with long ventriculo-atrial (VA) interval, ventricular rate of approximately 200 beats per



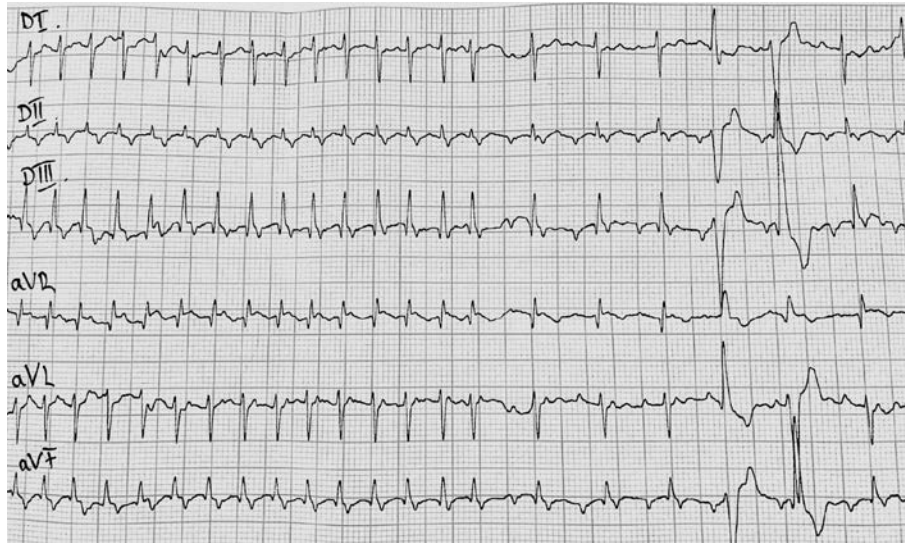
**FIGURE 1.** Pulsed Doppler echocardiogram from the fetus

minute (bpm), each ventricular beat being preceded by an atrial contraction (Figure 1). The fetus was free from signs of hydrops. In this clinical setting, the diagnosis of atrial tachycardia was established, and transplacental digoxin therapy was initiated. The next day, echocardiography revealed the persistence of fetal tachycardia and alteration of the hemodynamic status with the decrease of the flow through the major vessels. Thus, an emergency cesarean section was recommended.

After birth, electrocardiographic (ECG) strips showed a regular, narrow QRS, long-RP tachycardia with negative P waves in the inferior leads and a ventricular rate of 230 bpm. (Figure 2). The echocardiographic evaluation showed an ostium secundum-type atrial septal defect (ASD) and a large interatrial septum aneurysm. The newborn patient was clinically stable. Vagal maneuvers (ice immersion) were attempted. After the third attempt, a 2:1 atrioventricular (AV) block was observed, with the per-



**FIGURE 2.** Postnatal ECG strip showing a regular, narrow QRS, long-RP tachycardia, with negative P waves in the inferior leads and ventricular rate of 230 bpm

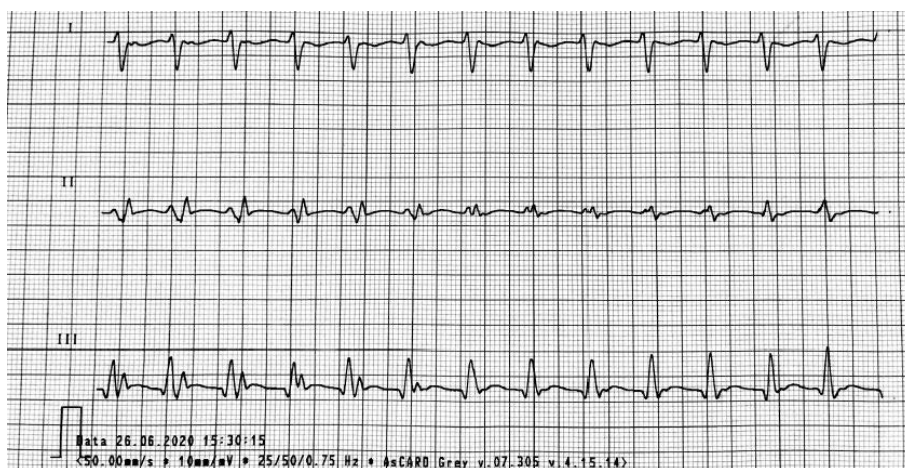


**FIGURE 3.** Vagal response showing 2:1 AV block, with the persistence of the tachycardia

sistence of the tachycardia, response suggestive for an AV node-independent tachycardia (Figure 3). Antiarrhythmic medication was initiated with amiodarone and digoxin. After a short period of time, due to the persistence of the tachycardia, as well as the alteration of the general status of the patient with mild edema, transesophageal overdrive pacing was attempted, without result (Figure 4). Thus, electrical cardioversion was applied, with the successful conversion of the tachyarrhythmia to sinus rhythm (HR 130 bpm). Intravenous amiodarone in a dose of 15 µg/kg/min was continued. In evolution, due to the relapse of the ectopic atrial tachycardia (EAT) with elevated ventricular rates (approximately 200 bpm), propranolol therapy was associated for rate control. On the third day of life, the clinical status of the patient began to worsen, thus a second electrical cardioversion was performed successfully.

The patient was in sinus rhythm approximately until three weeks of age, when ECG Holter monitoring revealed a significant number of atrial tachycardia runs, presenting abrupt on- and offset and a regular aspect. The arrhythmia was well tolerated hemodynamically, at a mean heart rate of 132 bpm, without clinical or echocardiographic signs of cardiac dysfunction. Thus, after the adjustment of the medical treatment (the propranolol dose was increased up to 2.3 mg/kg/day and amiodarone to 6.5 mg/kg/day), the patient was discharged. At follow-up after 1, 3, and 4 months, the patient was in good clinical condition, with no relapses.

The study was conducted according to the guidelines of the Declaration of Helsinki and approved by the Institutional Review Board of the Emergency Institute for Cardiovascular Diseases and Transplantation. Informed



**FIGURE 4.** Response to overdrive pacing

consent has been obtained from the patient's legal representative (parent) to publish this paper.

## DISCUSSION

Due to its immature structure, the delayed development of the atrioventricular fibrous annulus, and the presence of transient atrioventricular connections, the fetal myocardium is more likely to develop sustained tachycardia in comparison to neonates.<sup>1</sup>

Routinely, the evaluation of fetal arrhythmias can be performed by echocardiography, using M-mode and Doppler techniques, as fetal electrocardiography or magnetocardiography remain unused in the routine assessment of fetal arrhythmias due to technical limitations and reduced availability.<sup>1</sup> Identification of the pathophysiological mechanisms of the arrhythmia holds great prognostic value.

The most common tachyarrhythmia in fetal and early postnatal life is atrioventricular reentry tachycardia (AVRT).<sup>1</sup> Ventricular rates range between 230–280 bpm with minimal variability, displaying an abrupt onset and cessation, a 1:1 AV conduction with a shorter VA time interval compared to the AV interval (due to the rapid retrograde conduction via the accessory pathway and the slow antegrade conduction through the AV node – orthodromic AVRT).<sup>1,2</sup> In permanent junctional reciprocating tachycardia (PJRT), the anterograde limb of the reentry circuit is through the AV node, and the retrograde conduction is through a decremental slow-conducting pathway, resulting in a prolonged VA interval.<sup>1</sup> As in other reentry tachycardias, the on- and offset is sudden in PJRT, with an AV conduction of 1:1 and ventricular rates varying between 180–200 bpm.<sup>1</sup> Fetal atrial flutter (AFL) is the second most common mechanism of tachyarrhythmia and is due to an intra-atrial reentrant circuit. Atrial rates are usually between 300–550 bpm, with variable ventricular rates due to variable AV conduction.<sup>1</sup> Ectopic atrial tachycardia (EAT) is caused by the enhanced automaticity of myocardial cells. It can be characterized by a long VA interval, ventricular rates of 200–250 bpm, with beat-to-beat rhythm variability, and each ventricular depolarization is preceded by an atrial one, with a gradual on- and offset.<sup>1</sup>

Regarding the intrauterine evaluation of our patient, the considered differential diagnosis was either EAT or PJRT. Differentiation could not be made precisely due to the fact that the onset of the tachycardia could not be captured during echocardiography evaluation.

Optimal intrauterine arrhythmia management should be based on the condition of the fetus, the characteristics of the arrhythmia, gestational age, health status and willingness

of the mother to undergo treatment.<sup>1</sup> Medical treatment is usually recommended for fetuses with incessant tachycardia, with onset before 32 weeks gestational age and for those with a structurally abnormal heart.<sup>2</sup> Prior to the initiation of any transplacental antiarrhythmic medication, the evaluation of the mother is of great importance.<sup>1</sup> In fetuses with a gestational age of >35 weeks, with sustained or intermittent tachycardia, without signs of fetal hydrops, careful observation may be indicated or transplacental antiarrhythmic treatment may be attempted.<sup>1</sup> No prospective, standardized trials comparing antiarrhythmic agents have been conducted to determine optimal strategy guidelines.

In short VA interval tachycardia and AFL, in patients with no signs of hydrops, digoxin represents the first choice of treatment in most centers.<sup>2</sup> In hydropic fetuses, digoxin is not preferred due to limited transplacental transfer, and alternative medications, such as flecainide or sotalol, should be considered alone or in combination.<sup>1,2</sup> In the setting of long VA tachycardia, maternal medication with flecainide or sotalol can be recommended, with the association of digoxin if needed.<sup>2</sup>

In the case of our patient, according to current practice in our center, transplacental digoxin therapy was attempted. Several reasons sustained this decision. First, digoxin prolongs atrioventricular conduction, and together with vagal maneuvers, such as a light pressure applied on the maternal abdomen, can aid the diagnosis of intrauterine tachycardia. Second, transplacental therapy was initiated to help control the arrhythmia and avoid complications such as premature birth (the fetus being at 36–37 gestational weeks at the time of evaluation) or low weight at birth.

In the postnatal period, recording of a 12-lead ECG strip is of primordial importance in the diagnostic process of arrhythmias. When dealing with a narrow QRS complex tachycardia, several differential diagnostic criteria must be considered. Exclusion of an A-V reentrant mechanism can be made by blocking the AV node through the administration of an intravenous (i.v.) bolus of adenosine, or vagal maneuvers such as ice immersion, in which the persistence of tachycardia occurs in EAT, and the cessation of tachycardia run in AV reentry.<sup>3</sup> The electric response to the applied vagal maneuvers in our case consisted in the persistence of atrial tachycardia with a 2:1 AV block, thus excluding the presence of AV reentry circuits as the possible underlying mechanism of arrhythmia.<sup>4</sup> Atrial flutter was also ruled out due to the appearance of isolated P waves after vagal stimulation, instead of a typical saw-tooth pattern.

In the setting of EAT, P waves preceding each QRS complex can be visible but with different morphology than in sinus rhythm, while presenting a gradual acceleration

(“warm up”) and deceleration (“cool down”) behaviour.<sup>3</sup> EAT may also be characterized by suppression through overdrive, catecholamine responsiveness, and the inability to terminate with direct current cardioversion or vagal maneuvers.<sup>5</sup> Regarding the characteristics of the arrhythmia in our case, it presented some atypical features: abrupt on- and offset, non-responsiveness to overdrive pacing, the ability to terminate after direct current cardioversion, as well as its recurrent nature. These aspects led to the consideration of a possible intra-atrial reentry circuit involving the atrial septum aneurysm, as its tissue can represent an area with an altered refractory period.<sup>6</sup>

Considering the underlying mechanisms, EAT can be further categorized into abnormal automaticity or micro reentry circuits.<sup>6</sup> Wagner et al. reported a case of a newborn with focal micro reentry tachycardia (FMRT) with a possible correlation between the micro-reentry mechanism and an atrial septal aneurysm.<sup>6</sup> The correlation was established through examination of the surface ECG: positive P waves in leads II, III, avF, and V1–V4 made a septal origin of the focal ectopic reentry likely.<sup>6</sup> Several other cases have been described in the literature of neonates with atrial septal aneurysms and SVTs, but the relationship between the septal aneurysm and the mechanism of arrhythmia has remained controversial.<sup>7,8</sup> ECG recordings in our case showed P waves with characteristics that indicated a right low septal origin (including the ostium of the coronary sinus), thus the involvement of the septal aneurysm could be possible.

The overall prognosis of EAT is good. Children under three years of age are more likely to have spontaneous resolution of the arrhythmia.<sup>5</sup> Ablation may be necessary in severe cases that are refractory to antiarrhythmic treatment, particularly in older children.<sup>5</sup> Considering the prophylaxis of recurrence, antiarrhythmic treatment is warranted during the first 6–12 months.<sup>1</sup>

## CONCLUSION

In dealing with fetal or neonatal arrhythmias, a thorough echocardiographic evaluation is mandatory not only to

identify an underlying structural malformation, but also to evaluate the hemodynamic status. Despite the fact that in the intrauterine period the fetus was free from signs of hydrops, the hemodynamic condition quickly deteriorated and required an emergency delivery by cesarean section. Further research needs to be made concerning the underlying mechanism of arrhythmia in neonatal patients with an associated atrial septum aneurysm.

## FUNDING

This research was supported by the “George Emil Palade” University of Medicine, Pharmacy, Science and Technology of Târgu Mureş Research Grant number 10126/4/17.12.2020.

## CONFLICT OF INTEREST

Nothing to declare.

## REFERENCES

1. Howley L, Carr M. Fetal Arrhythmias. In: Da Cruz EM, Ivy D, Jaggars J, eds. *Pediatric and Congenital Cardiology, Cardiac Surgery and Intensive Care*. London: Springer, 2014; p. 271-291.
2. Brugada J, Blom N, Sarquella-Brugada G, et al. Pharmacological and non-pharmacological therapy for arrhythmias in the pediatric population: EHRA and AEPIC-Arrhythmia Working Group joint consensus statement. *Europace*. 2013;15:1337-1382.
3. Bromberg BI, Papez A. Atrial Ectopic Tachycardias. In: Macdonald D, ed. *Clinical Cardiac Electrophysiology in the Young*. 2nd Edition. London: Springer, 2015; p. 149-157.
4. Brugada J, Katritsis DG, Arbelo E, et al. 2019 ESC Guidelines for the management of patients with supraventricular tachycardia. The Task Force for the management of patients with supraventricular tachycardia of the European Society of Cardiology (ESC). *Eur Heart J*. 2020;41:655-720.
5. Escuerdo C, Blom NA, Sanatani S. Supraventricular Tachycardias. In: Da Cruz EM, Ivy D, Jaggars J, eds. *Pediatric and Congenital Cardiology, Cardiac Surgery and Intensive Care*. London: Springer, 2014; p. 2937-2971.
6. Wagner F, Gebauer R, Wagner R, Paech C. Supraventricular microreentry in a newborn due to a giant atrial septum aneurysm. *Clin Case Rep*. 2017;5:1654-1657.
7. Calderón CJ, Rijlaarsdam M, Chávez IM, Iturralde P. Interatrial aneurysm as a cause of supraventricular arrhythmia in a newborn infant. *Arch Inst Cardiol Mex*. 1995;65:143-147.
8. Morales R, Bokowski JW, Nguyen H, Awad SM. A Proposed Etiology for Atrial Tachyarrhythmia in Neonates with Atrial Septal Aneurysms. *Pediatr Cardiol*. 2019;40:230-233.