

# Chalk-induced Lung Fibrosis — Case Report

Zsuzsánna Ágnes Szász<sup>1,2</sup>, Enikő Székely-Vass<sup>2</sup>, Gyopár Horváth<sup>2</sup>, Mădălina Hozoi<sup>2</sup>

<sup>1</sup> Department of Occupational Medicine, University of Medicine and Pharmacy, Tîrgu Mureş, Romania

<sup>2</sup> Department of Occupational Medicine, Mureş County Hospital, Tîrgu Mureş, Romania

## CORRESPONDENCE

### Enikő Székely-Vass

Blv 1 Decembrie 1918 nr. 28  
540011 Tîrgu Mureş, Romania  
Tel: +40 759 021 307  
E-mail: sz\_v\_szoszi@yahoo.com

## ARTICLE HISTORY

Received: December 21, 2017  
Accepted: December 30, 2017

Zsuzsánna Ágnes Szász • Blv 1 Decembrie 1918, nr. 28,  
540011 Tîrgu Mureş, Romania. Tel: +40 265 263 585

Gyopár Horváth • Blv 1 Decembrie 1918, nr. 28,  
540011 Tîrgu Mureş, Romania. Tel: +40 265 263 585

Mădălina Hozoi • Blv 1 Decembrie 1918, nr. 28,  
540011 Tîrgu Mureş, Romania. Tel: +40 265 263 585

## ABSTRACT

**Introduction:** Our article underlines the importance of a good professional anamnesis, knowing all the chemical components with which the patient had been exposed to during her active life as a teacher. **Case presentation:** A 64-year-old female patient, teacher for 27 years, who had been retired for six years, presented cough with white phlegm and shortness of breath occurring during physical exertion, diffuse thoracic pain, and fatigue. Several lung functional tests were performed, which established the diagnosis of irreversible minor mixed ventilatory dysfunction. In order to establish the etiology of the patient's symptoms, multiple clinical, laboratory, imaging, and functional investigations were performed including a chest radiograph, pulmonary functional testing, bronchial reversibility testing, a thoracic CT scan, fibrobronchoscopy, alveolar-capillary diffusion capacity measurement, otorhinolaryngology examination, thyroid ultrasound, as well as a cardiological consult. Finally, a positive diagnosis was established: bronchial hyperreactivity syndrome, chalk dust-induced diffuse pulmonary fibrosis. **Conclusion:** An essential part of clinical practice is a proper anamnesis, including detailed information on the professional history and exposure, as well as the composition of the dust/particles with which the patient had been in contact with.

**Keywords:** chalk dust, pulmonary fibrosis, bronchial hyperreactivity, chronic cough

## INTRODUCTION

Pulmonary fibrosis is a condition in which fibrous tissue is formed in the pulmonary tissues. The accumulation of excess fibrous connective tissue causes a thickening of the alveoli, leading to blood hypoxia. As a consequence, patients present dyspnea.<sup>1</sup> Interstitial lung diseases (ILD) can be related to specific exposures, diseases associated with systemic conditions, and diseases of unknown cause.<sup>2</sup> Various causes for secondary pulmonary fibrosis include inhalation of environmental and professional toxins, such as metals, asbestos, or silica dust, and exposure to chalk dust, frequently cited as a source of fine particulate matter in schools.<sup>3</sup>

Chalk is a white sedimentary carbonated rock, a type of mineral composed of calcite. Recent studies showed that blackboard chalk contains mainly gypsum ( $\text{CaSO}_4$ ), calcite ( $\text{CaCO}_3$ ), dolomite ( $\text{CaMg}(\text{CO}_3)_2$ ), kaolinite, and some impurities such as silica and organic adhesives, in combination with different concentrations of trace elements such as Al, Cr, Mn, Fe, Co, Ni, Si, Pb.<sup>3-5</sup>

Since blackboard chalk is used as a writing tool by teachers, the amount of inhaled total dust, inorganic dust, non-SiO<sub>2</sub> inorganic dust, and calcium is significantly higher in the lung tissue.<sup>6,7</sup> Studies have been made on the association between professional exposure to chalk dust and respiratory disorders in school teachers, such as chronic bronchitis, asthma, upper respiratory tract symptoms, aphonia, and recurrent pulmonary tract infections, and also its relationship with pulmonary fibrosis.<sup>8,9</sup>

Pulmonary fibrosis is an illness where cough may be the predominant symptom. Does the illness cause the cough or is the cough (through its underlying etiology) the actual cause of the illness? — this is the key question asked throughout many studies. Cough hypersensitivity syndrome is the most accurate and convenient diagnosis that labels the patient's chronic cough. Starting from cough hypersensitivity syndrome as the primary diagnosis, it is essential to recognize the different phenotypes of allergic airway inflammation and, in most cases, a non-allergic inflammatory condition, thus providing a proper clinical and therapeutic management of these patients.<sup>10</sup>

The level of inflammation is linked to airway sensitivity, airway wall thickening, and airway hyperreactivity. Bronchial hyperresponsiveness (BHR) is described as an enhanced bronchial constriction triggered by different inhaled particles. It is considered a trademark of the inflammatory response in bronchial asthma and is related to the severity of the disease, being a clinical target for therapeutic interventions. Drawing a parallel, less is known about the mechanisms and frequency of BHR in subjects with chronic obstructive lung disease.<sup>11</sup>

Besides clinical examination, further tests are used to diagnose pulmonary fibrosis and BHR, such as lung functional testing and chest X-rays. Pulmonary fibrosis is a restrictive pulmonary disease, usually accompanied by reduced gas transfer, which may be marked clinically by desaturation after physical exertion.<sup>1,12</sup> Lung functional testing is used to diagnose the existing respiratory problem.<sup>13</sup> Studies on different professional categories have shown that airway obstruction due to chalk powder inhalation has significantly declined and, in addition, it was shown that the lower airflow parameters were significantly lower in workers from the chalk sacking area, with a higher concentration of dust in the workplace, compared to subjects from other workstations.<sup>3,13</sup>

## CASE PRESENTATION

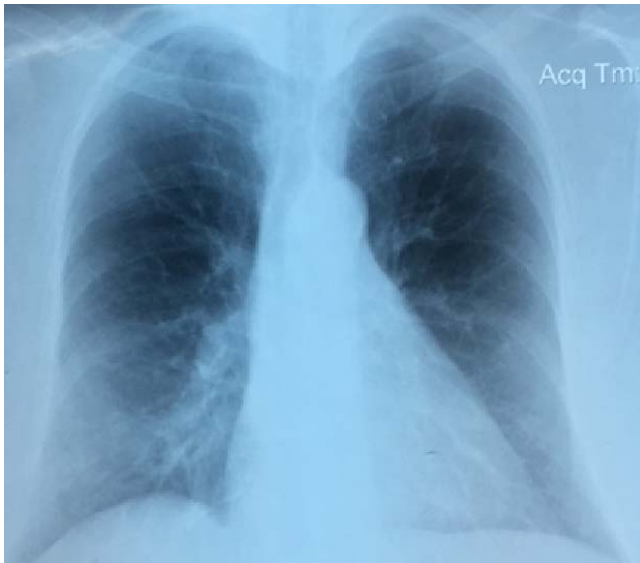We present the case of a 64-year-old female patient, non-smoker, who had been a teacher for 27 years and has been

retired for 6 years, with a medical history that included chronic cough since she had retired (around exposure cessation), mixed dyslipidemia, and cholecystectomy. The chronic cough persisted in the last 5–6 years, with less and more intense cough episodes, for which the patient was treated at the local hospital with antibiotics and symptomatic therapy in several occasions.

From the patient medical history, we can reveal that in January 2012 she presented cough with phlegm, thoracic pain, dyspnea, fatigue, and asthenia, and was diagnosed with right basal pneumonia for which she had been treated with antibiotics. After treatment, the patient did not present any improvement, neither in the clinical nor the radiological aspect from presentation, which led to the patient's referral to the local Pneumology Hospital. A lung functional testing was performed, which revealed a minor mixed ventilatory dysfunction, with the following results: forced vital capacity (FVC): 72%; forced expiratory volume in 1st second (FEV<sub>1</sub>): 74%; FEV<sub>1</sub>/FVC ratio: 112; peak expiratory flow rate (PEFR) or peak expiratory flow (PEF): 53%; forced expiratory flow 25–75% (FEF<sub>25–75%</sub>): 68%. Afterwards, in October 2014, the patient presented another respiratory infection, for which she was treated with a new series of antibiotics; otorhinolaryngology check-ups were also performed, but with inconclusive results. Moreover, the pulmonary functional testing was repeated, which showed a significant decrease in the measured lung parameters: FVC 59%; FEV<sub>1</sub> 65%; FEV<sub>1</sub>/FVC ratio 109; PEF 63%; FEF<sub>25–75%</sub> 78%, with a negative reversibility test. Fibrobronchoscopy and a CT scan were ordered, which excluded a malignant process, but confirmed the diagnosis of pulmonary fibrosis. For a proper differential diagnosis, a cardiological consult was performed, which excluded the presence of heart disease. Autoimmune diseases with lung involvement were also ruled out with laboratory testing of immunological markers. The established diagnosis was right basal pneumonia with suspicion of asthma, but the negative results of the bronchial reversibility test made this diagnosis improbable. The patient received antibiotics, inhalators, and systemic corticosteroid treatment, as well as antileukotrienes for three weeks.

The patient appeared at our medical office for the first time in February 2017, to investigate the occupational aspects of her existing pulmonary pathology, complaining of the following symptoms: chronic cough with difficult expectoration, and also periodically presenting cough crises with associated hoarseness, effort dyspnea, rhinorrhea, and palpitations.

During clinical examination, the pulmonary auscultation revealed rhonchi sounds, decreased vesicular breathing sounds, and a prolonged expiratory phase.



**FIGURE 1.** Posteroanterior chest X-ray: reticular, net-like shadowing of the lung, more predominant towards the lung bases; bilateral, middle-zone emphysema.

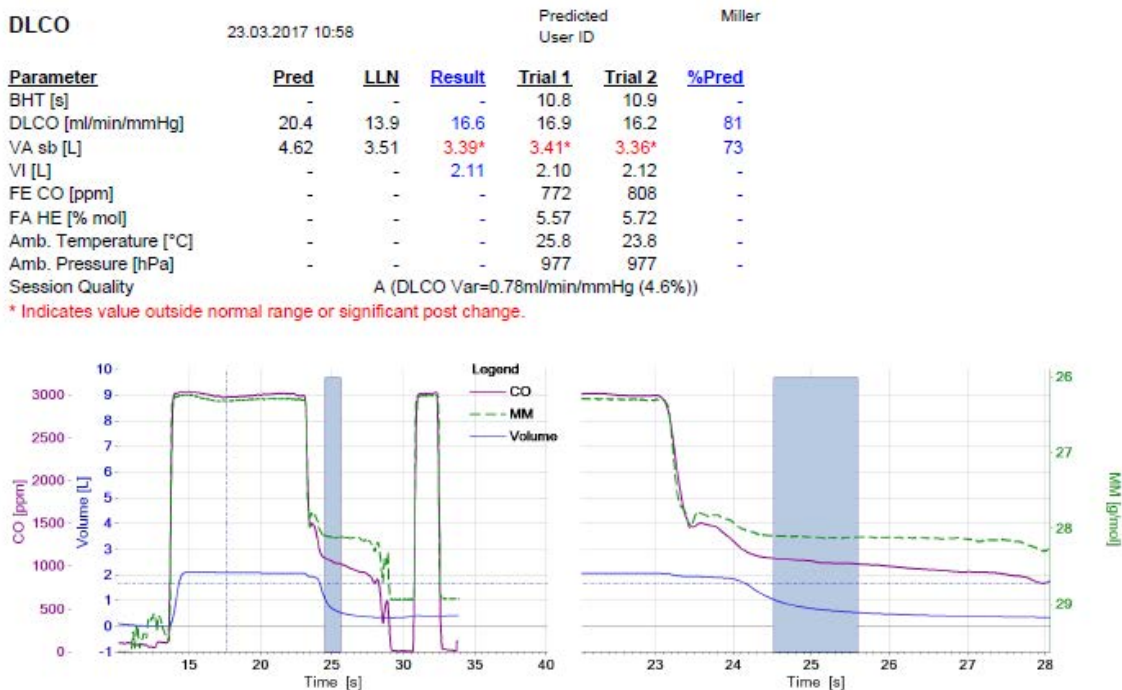
To exclude other etiologies regarding the patient’s symptoms, several tests were made, including nasal and pharyngeal swab (both came back negative), thyroid hormone test (within normal range), as well as thyroid

ultrasound, which showed chronic thyroiditis. The ENT check-up was repeated, but there were no significant pathological modifications found. The chest radiograph performed prior to hospitalization also excluded a mediastinal syndrome and confirmed the interstitial pulmonary fibrosis (Figure 1). Empiric antibiotic and inhalation therapy with long-acting beta-agonist bronchodilators (LABAs) in addition to inhaled corticosteroids (ICSs) had been started, with the recommendation of reevaluation after 30 days.

In March 2017, we repeated the lung functional testing and the bronchial reversibility test. The bronchial reversibility test was again negative for asthma: before bronchodilatation FVC: 59%; FEV<sub>1</sub>: 56%; FEV<sub>1</sub>/FVC ratio: 79.06; PEF: 51%; FEF<sub>25-75%</sub>: 38%; and after bronchodilatation: FVC: 63%, FEV<sub>1</sub>: 58%; FEV<sub>1</sub>/FVC ratio: 77.93; PEF: 58%; FEF<sub>25-75%</sub>: 45%.

The symptoms were still persisting despite the therapy with bronchodilators and inhaled corticosteroids combination.

The transfer factor of the lung for carbon monoxide was measured (Figure 2), with the following results: minor mixed ventilatory dysfunction with a diffusing capacity of the lung for carbon monoxide (DLCO) of 81% (normal range, but closer to the lower limit).



**FIGURE 2.** Parameters and graphs of DLCO determination. DLCO – 81% of predicted, normal range; VA – alveolar volume 73% of predicted, a decreased parameter

All these tests sustained the positive diagnosis: chalk dust-induced bronchial hyperreactivity syndrome and incipient diffuse interstitial pulmonary fibrosis. The recommended treatment consisted in the combination of long-acting beta agonists and inhaled corticosteroids with antileukotrienes and antihistamines.

In November 2017, the patient presented for a routine check-up after a viral respiratory infection, occurring two weeks prior, with associated cough crisis, which was predominant in the evening or after exposure to deodorant or other irritants, cold air or physical exertion. The clinical examination revealed decreased vesicular breath sounds, cough crisis during the lung functional test (the patient required administration of Salbutamol). Nevertheless, neither the patient's clinical status nor the pulmonary functional test did not show any improvement, but there was a slightly noticeable improvement on the distal bronchial segment (FVC: 59%, FEV<sub>1</sub>: 63%; FEV<sub>1</sub>/FVC ratio: 77.9; PEF: 60%; FEF<sub>25-75%</sub>: 67%). The patient required continuation of the recommended treatment until the next check-up.

The patient agreed to the publication of her data, and the institution where the patient had been admitted, approved the publication of the case.

## DISCUSSION

A recent study carried out in 2011 revealed that the most prevalent symptom of pulmonary fibrosis is hoarseness, and this respiratory disease is frequently associated with upper respiratory tract symptoms (URS) and chronic bronchitis, just like in the presented case.<sup>13</sup> As the presented case shows, it is important to know the patient's professional history, as well as the composition of the dust/particles with which the patient had been in contact.<sup>4</sup> Moreover, the patient's symptoms appeared at the end of her professional career.

As already proved in several studies, chalk dust can induce respiratory pathologies, mainly lung fibrosis, with bronchial inflammation and smooth muscle hypertrophy. All these may lead to airway narrowing and this may be the cause for smaller PEFr in teachers than control patients, just like in the presented case.<sup>3,7</sup>

Diffuse interstitial pulmonary fibrosis and bronchial hyperreactivity are reflected by a decrease in the functional parameters and shown by imaging methods, explaining the clinical aspect of our patient, mostly the chronic cough and dyspnea.

During the 5-year follow-up, there was a decline of up to 15% in the functional parameters, even in the absence of continued professional exposure and without any chron-

ic treatment. After the initiation of a chronic therapy for 6 months, the clinical evolution was stable, but there was no decline in the functional parameters. The treatment goal was to maintain the quality of life by controlling the cough, at least partially, and to treat the inflammatory component of the disease, thus preventing the progression of pulmonary fibrosis, even in the absence of exposure. The patient will be followed-up by determining the DLCO and repeating the FVC measurements and the high-resolution computed tomography, as it was recommended in an article by Korb and Collard, published in 2014, on idiopathic pulmonary fibrosis. This study also recommends applying a calculation formula and score (Gender, Age, Physiology variables: DLCO and FVC = GAP), for a correct staging of idiopathic pulmonary fibrosis, reflecting the severity of the prognosis of the disease as well.<sup>14</sup> Even if we cannot include the presented case in the idiopathic pulmonary fibrosis category, we consider it essential to use the above parameters to monitor the respiratory status of the patient.

## PARTYULARITY OF THE CASE

The symptoms first appeared after exposure cessation, and it must be mentioned that our patient was exposed to chalk dust for 27 years. The pathology was not correlated with the occupational exposure and the radiological imaging because the case was interpreted only in the context of acute lung disease, not as pulmonary fibrosis.

## CONCLUSIONS

An essential part of clinical practice is a proper anamnesis including detailed information on the professional history and exposure, as well as the composition of the dust/particles with which the patient had been in contact with. FVC, DLCO, and radiologic imagistic methods should be considered as follow-up parameters for monitoring the progress of the disease and also for evaluating treatment effectiveness.

## CONFLICTS OF INTEREST

Nothing to declare.

## REFERENCES

1. Agius R, Seaton A, Fletcher G, et al. Occupational and Environment Lung Disease. Relevant Fundamentals of Lung Structure and Function in Practical Occupational Medicine. 2nd ed. New York: Oxford University Press, 2005.
2. Chapmann JT. Interstitial Lung Disease in Thoracic Key. Available at: <https://thoracickey.com/interstitial-lung-disease/#s0040>
3. Nikam KD, Hirkani MA. Effects of Chalk dust on Peak Expiratory Flow Rate in School Teachers. *Int J Health Sci.* 2013;2:407-409.

4. Zhang YX, Yang ZH, Zhang QX, et al. Chemical compositions and effects on chemiluminescence of AMs in vitro of chalk dusts. *Chinese Chemical Letters*. 2015;26:157-159.
5. Maruthi YA, Ramprasad S, Lakshmana DN. Trace Elemental Characterization of Chalk Dust and Their Associated Health Risk Assessment. *Biol Trace Elem Res*. 2017;175:466-474.
6. Ohtsuka Y, Munakata M, Homma Y, et al. Three cases of idiopathic interstitial pneumonia with bullae seen in schoolteachers. *Am J Ind Med*. 1995;28:425-435.
7. Majumdar D, William SP. Chalk dustfall during classroom teaching: particle size distribution and morphological characteristics. *Environ Monit Asses*. 2009;148:343-351.
8. Rodilla R, José M, van der Haar R, et al: Association between occupational exposure to chalk dust and respiratory tract disease in school teachers. *Arch Prev Riesgos Labor*. 2011;14:88-95.
9. Miyake Y, Sasaki S, Yokoyama T, et al. Occupational and environmental factors and idiopathic pulmonary fibrosis in Japan. *Ann Occup Hyg*. 2005;49:259-265.
10. Morice AH. Chronic cough hypersensitivity syndrome. *Cough*. 2013;9:14.
11. Grootendorst DC, Rabe KF. Mechanism of bronchial hyperreactivity in asthma and chronic obstructive pulmonary disease. *Proc Am Thorac Soc*. 2004;1:77-87.
12. Brack T, Jubran A, Tobin MJ. Dyspnea and Decreased Variability of Breathing in Patients with Restrictive Lung Disease. *Am J Respir Crit Care Med*. 2002;165:1260-1264.
13. Bohadana AB, Massin N, Wild P, Berthiot G. Airflow obstruction in chalkpowder and sugar workers. *Int Arch Occup Environ Health*. 1996;68:243-248.
14. Kolb M, Collard HR. Staging of idiopathic pulmonary fibrosis: past, present and future. *Eur Respir Rev*. 2014;23:220-224.