

# Biventricular Hypertrophic Cardiomyopathy in a Child with LEOPARD Syndrome: a Case Report

Cristina Blesneac<sup>1</sup>, Carmen-Corina Şuteu<sup>2</sup>, Claudia Bănescu<sup>3</sup>, Theodora Benedek<sup>4</sup>, Imre Benedek<sup>4</sup>, Rodica Togănel<sup>2</sup>

<sup>1</sup> Department M4, Illrd Pediatric Discipline, Center for Advanced Medical and Pharmaceutical Research, University of Medicine and Pharmacy, Tîrgu Mureş, Romania

<sup>2</sup> Department M4, Illrd Pediatric Discipline, University of Medicine and Pharmacy, Tîrgu Mureş, Romania

<sup>3</sup> Genetics Laboratory, Center for Advanced Medical and Pharmaceutical Research, University of Medicine and Pharmacy, Tîrgu Mureş, Romania

<sup>4</sup> Department M3, Clinic of Cardiology, University of Medicine and Pharmacy, Tîrgu Mureş, Romania

## CORRESPONDENCE

### Carmen-Corina Şuteu

Str. Gheorghe Marinescu nr. 50  
540136 Tîrgu Mureş, Romania  
Tel: +40 745 534 554  
Email: suteucarmen@yahoo.com

## ARTICLE HISTORY

Received: October 23, 2017  
Accepted: November 7, 2017

**Cristina Blesneac** • Str. Gheorghe Marinescu nr. 38,  
540139 Tîrgu Mureş, Romania. Tel: +40 265 215 551

**Claudia Bănescu** • Str. Gheorghe Marinescu nr. 38,  
540139 Tîrgu Mureş, Romania. Tel: +40 265 215 551

**Theodora Benedek** • Str. Gheorghe Marinescu nr. 38,  
540139 Tîrgu Mureş, Romania. Tel: +40 265 215 551

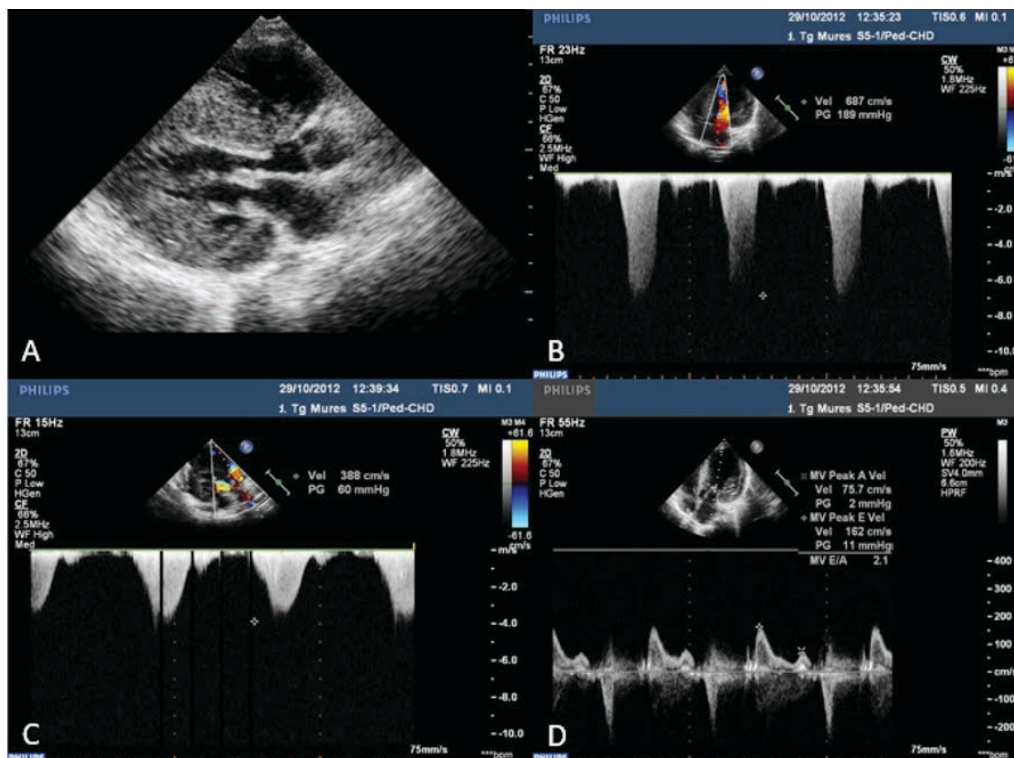
**Imre Benedek** • Str. Gheorghe Marinescu nr. 38,  
540139 Tîrgu Mureş, Romania. Tel: +40 265 215 551

**Rodica Togănel** • Str. Gheorghe Marinescu nr. 38,  
540139 Tîrgu Mureş, Romania. Tel: +40 265 215 551

## ABSTRACT

**Background:** LEOPARD syndrome is a complex dysmorphogenetic disorder of inconstant penetrance and various morphologic expressions. The syndrome is an autosomal dominant disease that features multiple lentigines, electrocardiographic changes, eye hypertelorism, pulmonary valve stenosis or hypertrophic cardiomyopathy, genital malformations, and a delayed constitutional growth hearing loss, which can be associated with rapidly progressive severe biventricular obstructive hypertrophic cardiomyopathy. No epidemiologic data are available on the real incidence of LEOPARD syndrome; however, this seems to be a rare disease, being often underdiagnosed, as many of its features are mild. **Case presentation:** We report the case of a 10-year-old female pediatric patient, diagnosed with obstructive hypertrophic cardiomyopathy at the age of 3 months, and recently diagnosed with LEOPARD syndrome. The patient first presented for a cardiologic examination at the age of 3 months, due to a murmur. She presented failure to thrive and psychomotor retardation, and was diagnosed with biventricular obstructive hypertrophic cardiomyopathy for which she had received high-dose beta-blocker therapy. At the age of 7 years she underwent a biventricular myectomy for relief of outflow tract obstruction, completed with another myectomy after 2 years due to progressive increase of pressure gradient in the left ventricular outflow tract. Prior to the second surgical intervention, multiple lentigines appeared on her skin, and genetic testing revealed the presence of LEOPARD syndrome. **Conclusion:** LEOPARD syndrome is a rare disease, which can be very difficult to diagnose, especially based on features other than lentigines. Cardiac involvement in LEOPARD syndrome can be progressive and requires multiple medical and surgical interventions.

**Keywords:** LEOPARD syndrome, hypertrophic cardiomyopathy, child



**FIGURE 1.** **A** – Transthoracic 2D-echocardiography, left parasternal long axis, showing severe symmetric HCM; **B** – CW Doppler interrogation of the left ventricular outflow tract, showing a peak gradient of 189 mmHg; **C** – CW Doppler interrogation of the right ventricular outflow tract, showing a peak gradient of 60 mmHg; **D** – evaluation of left ventricular diastolic function by PW Doppler interrogation at the tips of the mitral valve leaflets, showing severe diastolic dysfunction.

## INTRODUCTION

LEOPARD syndrome (LS) is an uncommon genetic autosomal dominant disease that includes the following entities: Lentigines, Electrocardiographic abnormalities, Ocular hypertelorism, Pulmonary stenosis, Abnormal genitalia, Retarded growth, and Deafness.<sup>1</sup>

The prevalence of this rare syndrome is not known precisely, though a minimum of 200 patients have been reported.<sup>2,3</sup>

LS is the result of different missense-mutations in one of 3 genes — PTPN11 = 90%, RAF1 <5%, BRAF <5%.<sup>1</sup>

Cardiac abnormalities found in patients with LS include electrocardiographic abnormalities and anatomical malformations, hypertrophic cardiomyopathy (HCM) being currently described as the most frequent abnormality (in up to 80% of cases).<sup>1</sup>

## CASE REPORT

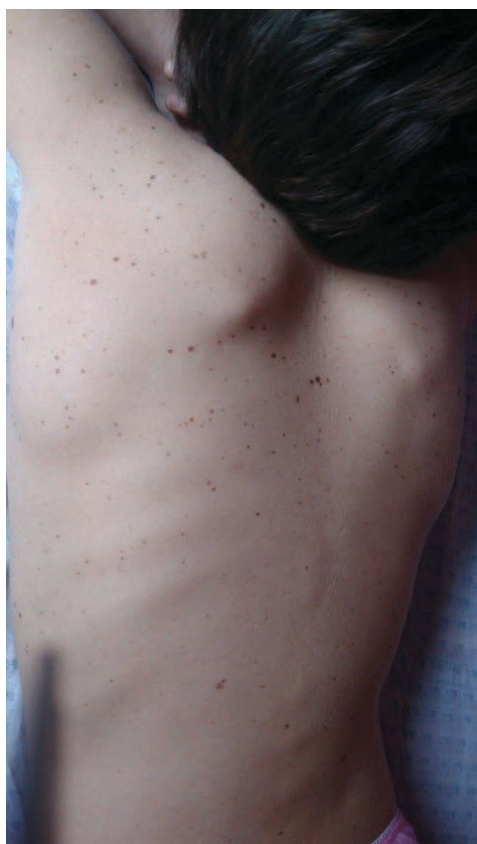We herein present the case of a 10-year-old female pediatric patient, who first presented for a cardiologic examination in infancy, at the age of 3 months, due to a murmur.

Her family history was positive for HCM, having an aunt diagnosed with HCM, who died suddenly at the age of 35.

At time of the first cardiac evaluation, she presented failure to thrive and psychomotor retardation. She was diagnosed with biventricular obstructive HCM, for which beta-blocker therapy was initiated, with incremental dosage.

At the age of 7 years she presented with decreased exercise capacity, growth retardation (BW: 17 kg, H: 109 cm), and pallor, without any other changes at the skin level. She also presented mild psychic retardation and polymorphic dyslalia. The electrocardiogram revealed both left and right ventricular hypertrophy, and impaired repolarization. An intermittent inferior atrial rhythm was found at the 24-hour ECG Holter monitoring.

The echocardiography showed severe biventricular obstructive HCM, with a peak gradient of 190 mmHg in the left ventricular outflow tract (LVOT), and of 60 mmHg in the right ventricular outflow tract (RVOT), respectively. Severe diastolic dysfunction of the left ventricle was also found (Figure 1). No pulmonary valvular stenosis was found in this patient.



**FIGURE 2.** Multiple lentiginos on the posterior chest wall and shoulders

The patient underwent a Morrow myectomy for relief of the LVOT obstruction, and right myectomy for relief of the RVOT obstruction. Immediately after surgery, she presented a transitory complete AV block, but with subsequent spontaneous recovery of the sinus rhythm.

At the 3-month follow-up after surgery, the peak gradient was 70 mmHg in the LVOT and 15 mmHg in the RVOT. Left ventricular diastolic dysfunction remained severe, and beta-blocker therapy was continued after surgery.

One year after surgery, at the age of 9, multiple lentiginos appeared on the patient's skin (Figure 2). She presented reduced exercise capacity, fatigability, palpitations, and angina. At that point, echocardiography revealed an increase in the peak pressure gradient in the LVOT to 115 mmHg, a medium mitral regurgitation, but with no significant residual obstruction in the RVOT.

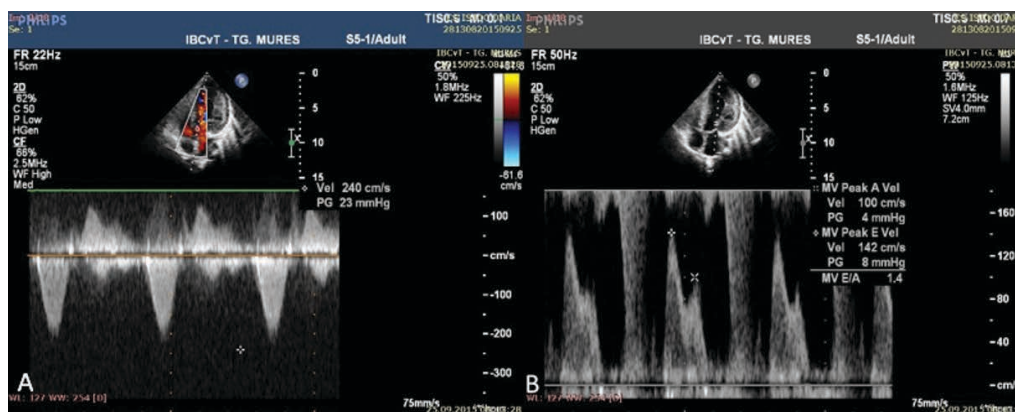
The patient underwent a second extensive Morrow myectomy for relief of the LVOT, at only two years after the first intervention.

At that point, genetic testing was carried out, which identified a missense-mutation of the PTPN11 gene, the patient being consecutively diagnosed with LEOPARD syndrome. No deletions and duplications were identified by multiplex ligation-dependent probe amplification (MLPA) technique for 35 of the 40 exons of MYH7 gene and for 29 of the 35 exons for MYBPC3 gene, the two genes most frequently involved in the pathogenesis of HCM.

At the 3-month follow-up after the second surgery, echocardiography revealed a significant decrease in the LVOT obstruction, with a peak residual gradient of 23 mmHg at that level and improvement of the left ventricle diastolic function (Figure 3).

After the second myectomy, exercise capacity of the patient had improved, and she no longer presented angina.

The legal guardians/parents of the pediatric patient agreed to the publication of her data and the institution where the patient had been admitted, approved the publication of the case.



**FIGURE 3.** **A** – CW Doppler interrogation of the left ventricular outflow tract, showing a peak gradient of 23 mmHg; **B** – evaluation of left ventricular diastolic function by PW Doppler interrogation at the tips of the mitral valve leaflets, showing normal diastolic function.

## DISCUSSIONS

LS is a rare “neuro-cardio-facial-cutaneous” genetic syndrome, first described by Zeisler and Becker in 1936, in a woman aged 24 years, who presented generalized lentiginosities, hypertelorism, pectus carinatus, and prognathism.<sup>1</sup> In 1962, Moynahan described the syndrome in association with cardiac anomalies and short stature.<sup>1</sup>

LS is more frequently inherited as an autosomal dominant trait, but sporadic cases are also described.<sup>4</sup> In 90% of the cases, LS occurs due to a missense type of mutation in PTPN11 gene, other involved genes being RAF1 and BRAF, each implicated in less than 5% of cases.<sup>1</sup> In our case a missense-type mutation in PTPN11 gene was also found.

The acronym of LS results from the first letters of the major signs and symptoms of the disorder: lentiginosities (100%); electrocardiographic abnormalities (75–80%); ocular hypertelorism (75%); pulmonary stenosis or HCM (comprising 95%); abnormal genitalia (50%); retarded growth (40–50%), and deafness (15–25%), showing that in LS, clinical manifestations are highly variable.<sup>1</sup>

The diagnostic hallmark of LS are lentiginosities, which sometimes become apparent only after puberty.<sup>5,6</sup> In our case, lentiginosities only appeared when the girl was 9 years old, genetic testing being performed afterwards, revealing LS.

The presence of lentiginosities and two other symptoms allow a clinical diagnosis. When lentiginosities are missing, the clinical diagnosis can be made in the presence of three symptoms and one first-line relative diagnosed with LS.<sup>7,8</sup> In our case, besides lentiginosities, three other criteria were present — electrocardiographic abnormalities, HCM, and retarded growth. Other signs and symptoms were not found, this being consistent with the clinical heterogeneity of the disease.

In LS, the most frequently associated cardiac abnormality is HCM, occurring in about 80% of cases, while about 30% of patients have right ventricular hypertrophy, and in up to 40% of cases a significant obstruction of the LVOT may be associated.<sup>1,9,10</sup> In our patient, a biventricular hypertrophy was diagnosed.

Cardiac disease in LS can be progressive, patients with such anomalies requiring periodic assessment.<sup>4</sup> In our case, the severity of HCM progressed over the years, requiring two surgical interventions for relief of the ventricular outflow tracts. Although the onset of disease was in early infancy, cardiac disease in this patient cannot be included in the category of critical congenital heart disease.<sup>11</sup>

When the associated cardiac anomalies are only mild, the long-term prognosis of LS seems to be benign, while the association of HCM in LS patients increases the risk for adverse events during follow-up.<sup>12</sup> The phenotype with a

severe, obstructive left ventricular hypertrophy (as in the present case) may represent a risk factor for adverse clinical outcome in patients with LS and HCM, in whom a close monitoring and follow-up is mandatory. There were no adverse events developed during the follow-up in our case.

## CONCLUSION

LEOPARD syndrome is a rare disease, which can be very difficult to diagnose, especially based on features other than lentiginosities, and identification of LS in infants and young children can represent a challenge. Cardiac involvement in LEOPARD syndrome can be progressive and requires multiple medical and surgical interventions.

## ACKNOWLEDGEMENT

This paper was carried out in the research project no 17800/7/22.12.2015, financed through Internal Research Grants by the University of Medicine and Pharmacy Țirgu Mureș, Romania.

## CONFLICT OF INTEREST

Nothing to declare.

## REFERENCES

1. Dzemeshkevich S, Frolova J, Betekhtin M, Shapieva A, Rizun L. The case of a 17-year old male with LEOPARD syndrome. *Journal of Cardiology Cases*. 2013;7:e37-e41.
2. Carcavilla A, Santome JL, Pinto I, et al. LEOPARD Syndrome: a variant of Noonan syndrome strongly associated with hypertrophic cardiomyopathy. *Rev Esp Cardiol*. 2013;66:350-356.
3. Sarkozy A, Digilio MC, Dallapiccola B. LEOPARD syndrome. *Orphanet J Rare Dis*. 2008;3:13.
4. Ganigara M, Prabhu A, Kumar RS. LEOPARD syndrome in an infant with severe hypertrophic cardiomyopathy and PTPN11 mutation. *Ann Pediatr Card*. 2011;4:74-76.
5. Digilio MC, Sarkozy A, De Zorzi A, et al. LEOPARD syndrome: clinical diagnosis in the first year of life. *Am J Med Genet*. 2006;140:740-746.
6. Sarkozy A, Schirizzi A, Lepri F, et al. Clinical lumping and molecular splitting of LEOPARD and NF1/NF1-Noonan syndromes. *Am J Med Genet A*. 2007;143A:1009-1011.
7. Tartaglia M, Martinelli S, Stella L, et al. Diversity and functional consequences of germline and somatic PTPN11 Mutations in human disease. *Am J Human Genet*. 2006;78:279-290.
8. Voron DA, Hatfield HH, Kalkhoff RK. Multiple lentiginosities syndrome. Case report and review of the literature. *Am J Med*. 1976;60:447-456.
9. Limongelli G, Pacileo G, Marino B, et al. Prevalence and clinical significance of cardiovascular abnormalities in patients with LEOPARD syndrome. *Am J Cardiol*. 2007;100:736-741.
10. Limongelli G, Sarkozy A, Pacileo G, et al. Genotype-phenotype analysis and natural history of left ventricular hypertrophy in LEOPARD syndrome. *Am J Med Genet Part A*. 2008;146:620-628.
11. Toganel R. Critical congenital heart disease as life-threatening conditions in the Emergency Room. *Journal of Cardiovascular Emergencies*. 2016;2:7-10.
12. Woywodt A, Welzel J, Haase H, et al. Cardiomyopathic Lentiginosis/LEOPARD Syndrome presenting as sudden cardiac arrest. *Chest*. 1998;113:1415-1417.